In The Name of GOD

Treatment for resectable pancreatic cancer

Asieh Hatefi , MD

Gastroenterologist and Hepatologist

Mashhad University Of Medical Sciences

Jan-2025



- The treatment of resectable exocrine pancreatic cancer has evolved significantly over the years
- Surgical resection offers the only chance of cure for exocrine pancreatic cancer
- Only 15 to 20 percent of cases are potentially resectable at presentation
- Local unresectability : usually (but not always) due to vascular invasion

potentially resectable exocrine pancreatic cancers

Who has potentially resectable disease?

- No distant metastatic disease
- An appropriate performance status and comorbidity profile for major abdominal surgery
- No radiographic interface between the primary tumor and the mesenteric vasculature as assessed by cross sectional imaging

	Vascular Structure	Localised and Resectable	Borderline Resectable	Locally Advanced
Pancreatic Head	Arteries	No arterial abutment, clear fat plane with CA, CHA and SMA	CHA abutment or encasement; no extension to the celiac axis < 180 degree SMA, no CA encasement	> 180 degree abutment of SMA or any CA abutment Aortic invasion
	Veins	No venous abutment, clear fat plane with MPV and SMV	MPV or SMV encasement with reconstructible MPV or SMV	Unreconstructible MPV or SMV
Pancreatic Body or Tail	Arteries	No arterial abutment, clear fat plane with CA, CHA and SMA	< 180 degree SMA, or CA encasement	> 180 degree abutment of SMA or CA abutment
	Veins	No venous abutment, clear fat plane with MPV and SMV	Reconstructible MPV or SMV	Unreconstructible MPV or SMV

Table 1 National Comprehensive Cancer Network guidelines on resectability criteria
Legend: *CA: celiac axis, CHA: common hepatic artery, SMA: superior mesenteric artery, MPV: main portal vein, SMV: superior mesenteric vein*

Group	What does it mean?	Can surgery be done?	Why?
Resectable	Cancer has not spread outside the pancreas.	Yes, tumor can be removed completely with surgery.	Tumor has not grown into nearby arteries or veins.
Borderline resectable	It is hard to tell from imaging tests if the cancer has spread to nearby tissues.	It is unclear if the tumor can be removed with surgery.	Tumor may or may not have grown into nearby arteries and veins.
Locally advanced	There is cancer (metastasis) in nearby lymph nodes and tissues.	Tumor may or may not be removed with surgery. Lymph nodes may be resectable.	Tumor has grown into nearby lymph nodes and tissues.
Metastatic	Cancer has spread to distant	No, tumor cannot be	Tumor has grown into surrounding tissues and has

Unresectable PC

- Metastases (liver, peritoneum, omentum, or any extra-abdominal site)
- Local unresectability :
  encasement (more than one-half of the vessel circumference) or occlusion/thrombus of the SMA, Unreconstructable SMV or SMV/portal vein confluence occlusion
  Direct involvement of the IVC, aorta, or celiac axis
- Management of these locally advanced but unresectable : usually initial chemotherapy and not surgical exploration
- Absolute contraindications to resection

Continuum of resectability for pancreatic adenocarcinoma

HIGH

RESECTABILITY

LOW

- No distant metastases
- No arterial or venous involvement
- Attachment to other organs (eg, spleen)
- Venous involvement (SMV or portal) less than 180 degrees, as long as there is suitable vessel proximal and distal to the areas of involvement for reconstruction
- Gastroduodenal artery encasement up to the common hepatic artery with other short segment encasement or abutment of the hepatic artery, but without extension to celiac trunk
- Tumor abutment of the SMA less than one-half the circumference of the vessel wall.
- Greater than 180 degree encasement or occlusion/thrombus of SMA, unreconstructable SMV or SMV-portal vein confluence occlusion
- Direct involvement of the inferior vena cava, aorta, celiac trunk or hepatic artery, as defined by absence of a fat plane between low density tumor and these structures on CT or EUS.
- Metastases to lymph nodes beyond the peripancreatic tissues
- Distant metastases

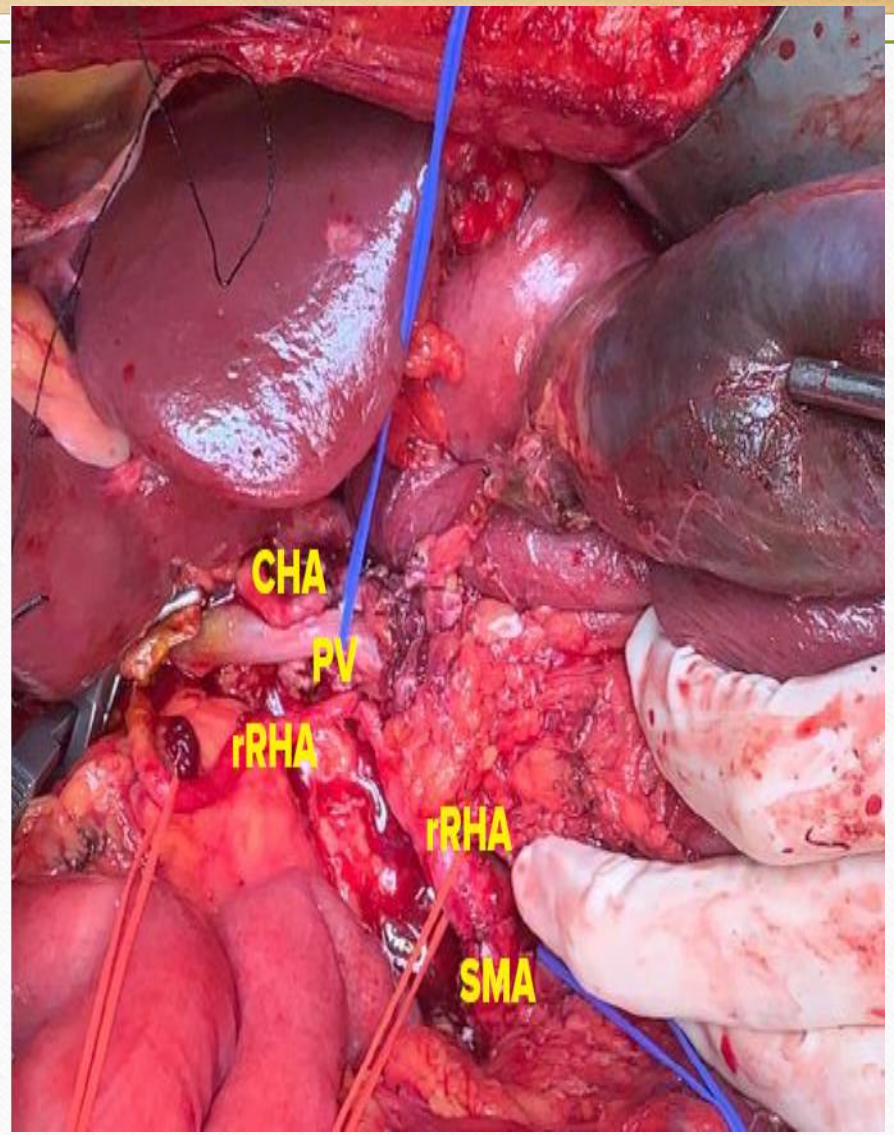

Copyrights apply

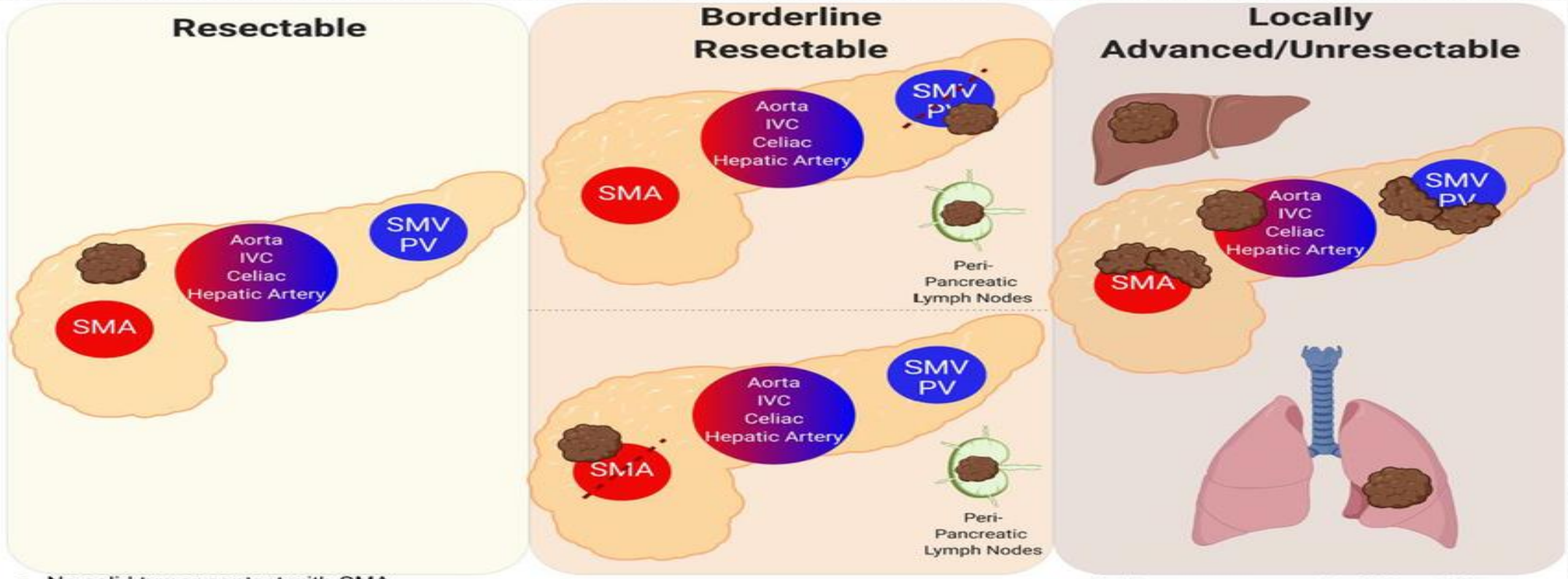

- No solid tumor contact with SMA
- No solid tumor contact with Celiac axis
- No solid tumor contact with IVC or Aorta
- No SMV or PV involvement
- No distant metastases
- No metastases to peri-pancreatic nodes
- CA19-9 close to or within normal limits

- Solid tumor contact with SMA < 180°
- Solid tumor contact with Celiac axis < 180°
- If involved, reconstructable SMV or PV
- No distant metastases
- Lymph node metastasis to resectable peri-pancreatic nodes
- Elevated CA19-9 (>150)

- Solid tumor contact with SMA > 180°
- Solid tumor contact with Celiac axis > 180°
- Aortic involvement
- Unreconstructable SMV or PV due to tumor invasion or occlusion
- Distant metastases to different organs or lymph nodes
- Elevated CA19-9 (>150)

Contribution of serum tumor markers (CA 19-9)

Preoperative serum CA 19-9 levels:

- should not be used to direct the initial treatment strategy
- Help to predict the presence of radiographically occult metastatic disease, the likelihood of a R0 resection, and long-term outcomes in patients with potentially resectable pancreatic cancer
- Better select patients who need staging laparoscopy
- the ASCO and NCCN guideline suggest that chemotherapy could be used before surgery for patients who had potentially anatomically resectable but high-risk tumors
- No specific cutoff value of CA 19-9 to select patients for neoadjuvant therapy

Multidisciplinary assessment and symptom burden

- Multidisciplinary collaboration to formulate treatment plans is preferred:

Baseline performance status
Comorbidity profile
Goals of care
Patient preferences
Psychologic status
Support systems
Symptoms

- Need for formal palliative care consultation and services can improves clinical and quality of care outcomes, and may prolong survival.

Preoperative biliary drainage

Endoscopically placed stent prior to surgery for patients :

- Serum bilirubin concentration > 20 mg/dl
- Delayed surgery for longer than two weeks (particularly if neoadjuvant therapy is chosen)
- Debilitating pruritus
- Cholangitis

Treatment of exocrine pancreatic cancer

Prognosis : poor, (even for those undergoing mic complete (R0) resection:

High rates of both systemic (>80 percent) and local (>20 percent) recurrence after surgery alone

systemic chemotherapy, radiation therapy, and combined approaches (chemoradiotherapy) prior to and following surgical resection to improve cure rates

- Neoadjuvant strategies for locally advanced, unresectable or "borderline" r
- Surgical management of localized exocrine pancreatic cancer
- Chemotherapy for advanced disease

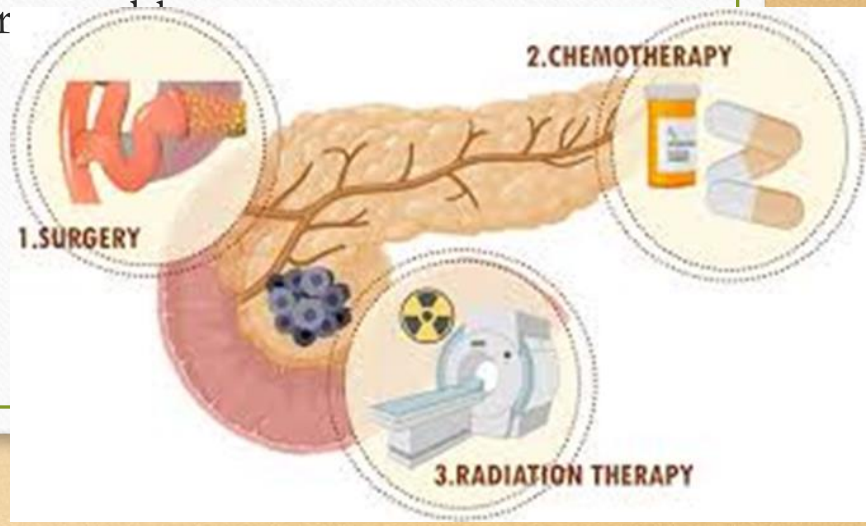

Treatment

	Recommended management	Evidence	Comments
Resectable	Surgical resection → 6 months of postoperative chemotherapy or preoperative chemotherapy with or without chemoradiotherapy → surgical resection → postoperative chemotherapy	Adjuvant gemcitabine plus capecitabine[74] and mFOLFIRINOX[78] both showed improved OS in phase 3 studies; neoadjuvant chemotherapy is increasingly used, with retrospective data suggesting improved survival,[84] but lack of strong evidence precludes routine use	Consider mFOLFIRINOX only for patients with ECOG performance status of 0 or 1; if preoperative chemotherapy is given, total duration of chemotherapy should be 6 months; advise clinical trial enrolment
Borderline resectable	Same as for resectable	Subgroup analysis from PREOPANC-1 study showed improved survival with preoperative chemotherapy and chemoradiotherapy[85]	Same as for resectable
Locally advanced	Systemic chemotherapy → surgical resection for down-staged patients	Multiple phase 2 and 3 studies of first-line systemic chemotherapy for locally advanced disease show benefit of induction chemotherapy[86]	For non-operative patients not progressing on chemotherapy, consider consolidative chemoradiotherapy or treatment break; no OS benefit found for chemoradiotherapy in this setting;[55] advise clinical trial enrolment
Metastatic	Systemic chemotherapy	FOLFIRINOX[57] or gemcitabine plus nab-paclitaxel[93] as first-line regimens in phase 3 studies showed improved OS when compared to gemcitabine alone	Consider FOLFIRINOX only for patients with ECOG performance status of 0 or 1; supportive care is a crucial component of management of advanced pancreatic cancer; advise clinical trial enrolment

mFOLFIRINOX=modified FOLFIRINOX (5-fluorouracil, folinic acid [leucovorin], irinotecan, and oxaliplatin). OS=overall survival. ECOG=Eastern Cooperative Oncology Group.

Lancet 2020; 395: 2008–20

- Although guidelines from ASCO and NCCN suggest that neoadjuvant therapy could be offered to certain "high-risk" patients with initially resectable disease, including those with a high initial CA 19-9 , in our view, preoperative serum CA 19-9 levels should not be used to direct the initial treatment strategy

Initial resection versus neoadjuvant therapy

- For potentially resectable :
- neoadjuvant therapy to be a reasonable alternative to upfront surgery followed by adjuvant Surgery
- Further studies are necessary to clarify the optimal approach (encourage patients to enroll in CT)
- Given the poor outcomes with upfront surgery: neoadjuvant combination chemotherapy for initial therapy of borderline resectable pancreatic cancer, followed by re-evaluation for surgical exploration (preferred approach)
- nearly all patients who appear to have "potentially resectable" pancreatic cancer should in fact be considered to have "borderline resectable" disease (inaccuracy of imaging and the very high rates of a positive resection margins with initial surgery)
- Data from prospective randomized trials and a meta-analysis support benefit for neoadjuvant therapy in combined populations of patients with potentially resectable or borderline resectable pancreatic cancer

Upfront pancreatectomy versus neoadjuvant therapy

- For patients with potentially resectable exocrine pancreatic cancer: either treatment strategy
- Primary surgical resection is an appropriate option for patients with:
  - No distant metastatic disease
  - An appropriate performance status and comorbidity profile for major abdominal surgery
  - No radiographic interface between the primary tumor and the celiac axis, SMA, or CHA
- For others: initial chemotherapy rather than upfront surgery

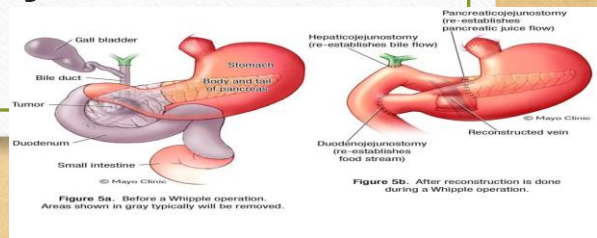

Figure 5a. Before a Whipple operation. Areas shown in gray typically will be removed.

Figure 5b. After reconstruction is done during a Whipple operation.

Adjuvant chemotherapy

- For all patients who undergo upfront pancreatectomy, (T1N0 disease: six months of adjuvant chemotherapy
- Adjuvant treatment should be started within eight weeks of surgery, if possible, and preceded by restaging with CT scans and a serum level of the tumor marker CA 19-9
- Suggestion approach (Off protocol) :

✓ Excellent performance status: modified FOLFIRINOX (oxaliplatin plus irinotecan with leucovorin and short-term infusional fluorouracil

✓ Less fit patients: gemcitabine plus capecitabine or gemcitabine plus nabpaclitaxel

✓ Borderline performance status or a comorbidity profile (precludes multiagent therapy) : gemcitabine alone ,S-1, (more effective)

Adjuvant chemoradiotherapy

- do not offer adjuvant CRT to individuals who have had a six-month adjuvant course of FOLFIRINOX
- reserve for selected patients who desire highly aggressive therapy and retain an excellent performance status after surgery and chemotherapy.
- For most patients who have received a gemcitabine-based adjuvant chemotherapy regimen, we suggest the addition of concurrent CRT to chemotherapy

Patients selected for neoadjuvant therapy

If neoadjuvant therapy is planned, a tissue diagnosis is required before initiation of therapy

- **Neoadjuvant regimen** – For most patients who are able to tolerate it, we suggest the multiagent modified FOLFIRINOX regimen followed by CRT
- Other options : gemcitabine-based CRT and chemotherapy without radiation.
- Surgery could then be reconsidered at a later time if appropriate.
- **Adjuvant therapy** – After resection, we suggest a total of six months of systemic therapy, to include the preoperative regimen
- For patients with an excellent performance status, we suggest modified FOLFIRINOX . For less fit patients, alternatives include gemcitabine plus capecitabine , gemcitabine plus nabpaclitaxel , gemcitabine alone or, where available, S-1 alone.

Post-treatment surveillance

- A history and physical examination and check CA 19-9 level (if initially elevated) every six months for two years, then annually
- not routinely obtain follow-up CT scans after pancreaticoduodenectomy, (unless indicated by symptoms or a rising CA 19-9 level).
- Others disagree, and follow the consensus-based guidelines of the NCCN: follow-up CT scans every three to six months for at least two years, then every 6 to 12 months

Treatment algorithm for nonmetastatic exocrine pancreatic cancer

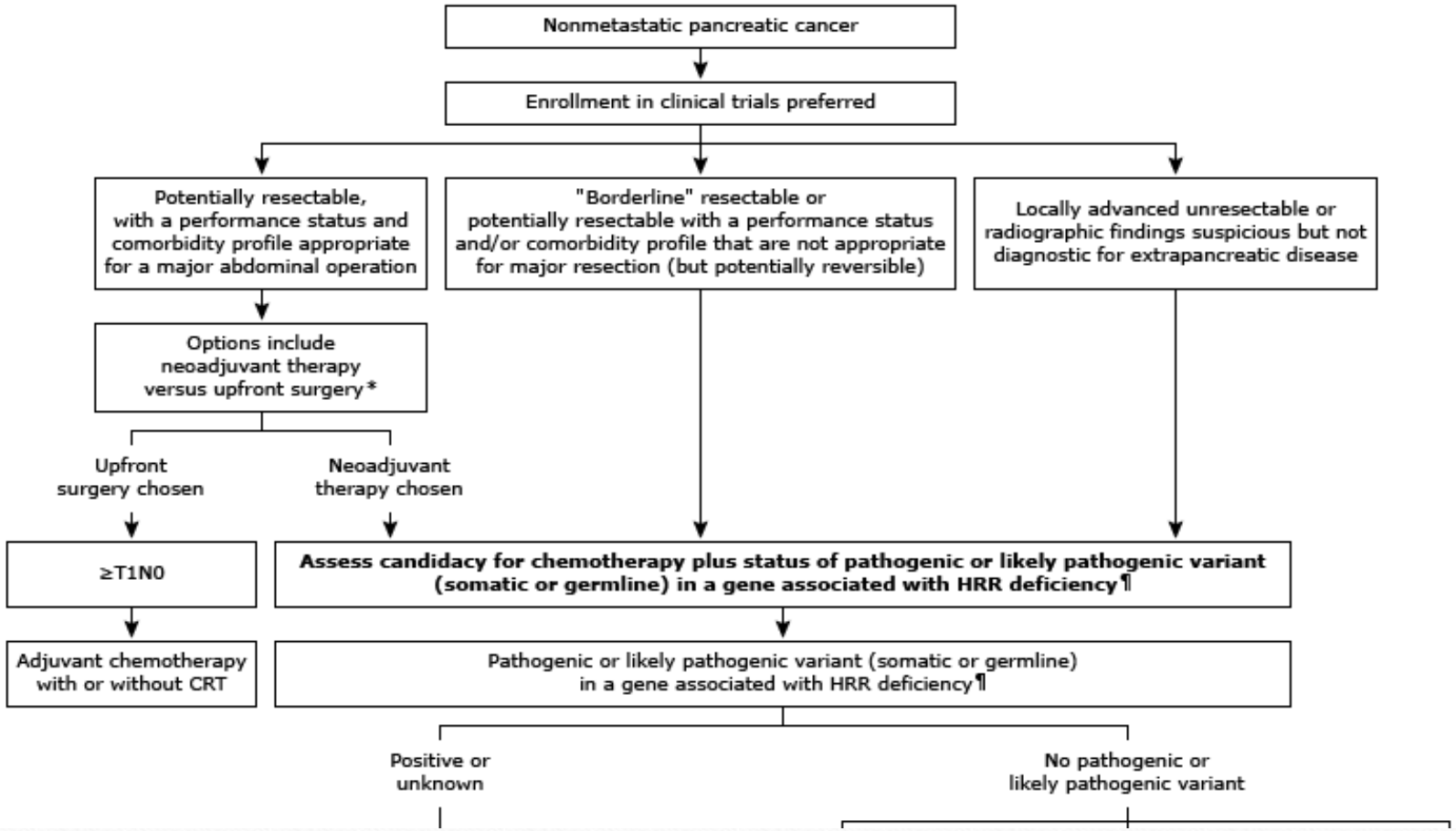

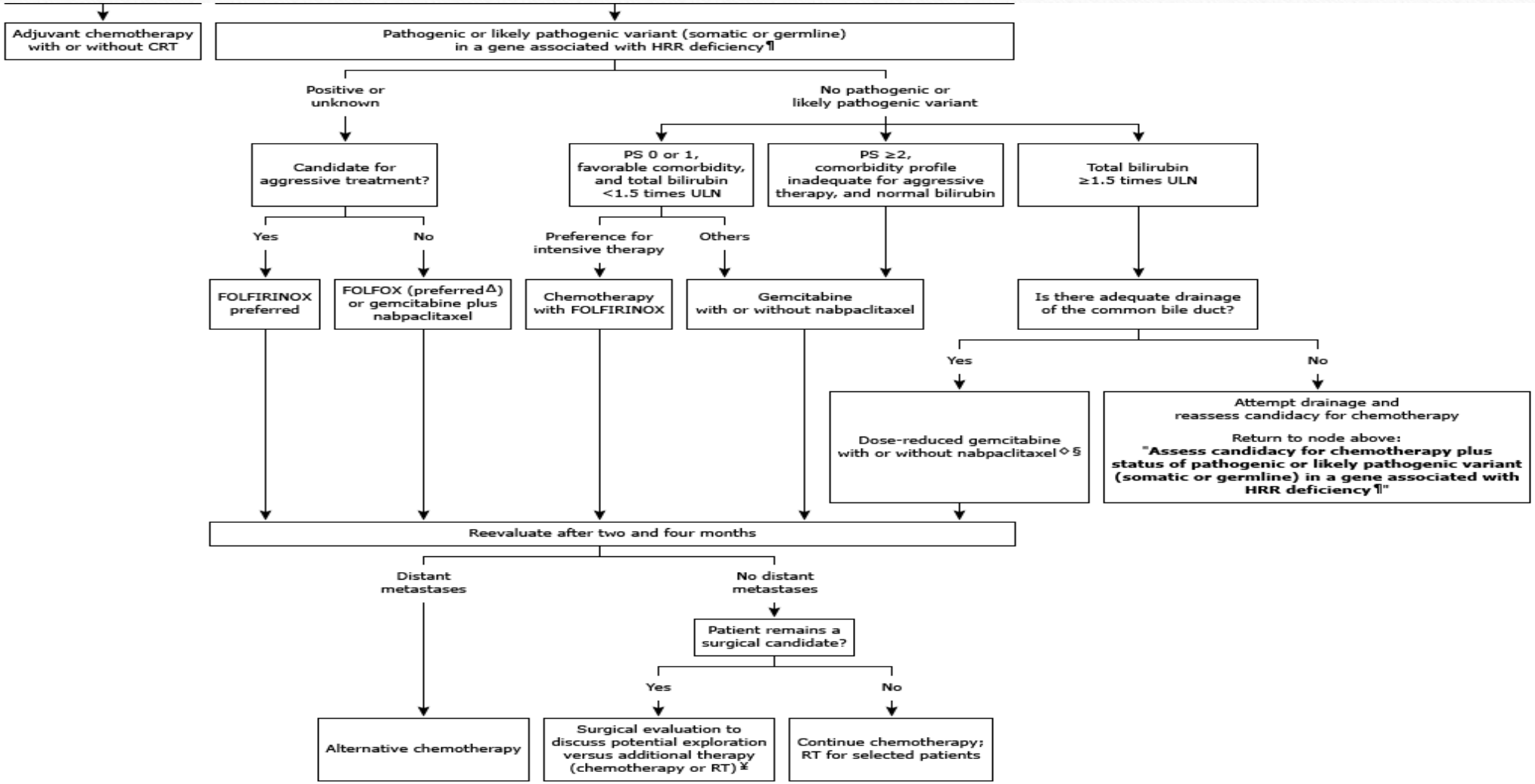
Adjuvant chemotherapy with or without CRT
Pathogenic or likely pathogenic variant (somatic or germline) in a gene associated with HRR deficiency ¶
Positive or unknown
No pathogenic or likely pathogenic variant
Candidate for aggressive treatment?
PS 0 or 1, favorable comorbidity, and total bilirubin <1.5 times ULN
PS ≥2, comorbidity profile inadequate for aggressive therapy, and normal bilirubin
Total bilirubin ≥1.5 times ULN
Yes
No
Preference for intensive therapy
Others
FOLFIRINOX preferred
FOLFOX (preferred Δ) or gemcitabine plus nabpaclitaxel
Chemotherapy with FOLFIRINOX
Gemcitabine with or without nabpaclitaxel
Is there adequate drainage of the common bile duct?
Yes
No
Dose-reduced gemcitabine with or without nabpaclitaxel ◇ §
Attempt drainage and reassess candidacy for chemotherapy
Return to node above: "Assess candidacy for chemotherapy plus status of pathogenic or likely pathogenic variant (somatic or germline) in a gene associated with HRR deficiency ¶"
Reevaluate after two and four months
Distant metastases
No distant metastases
Patient remains a surgical candidate?
Yes
No
Alternative chemotherapy
Surgical evaluation to discuss potential exploration versus additional therapy (chemotherapy or RT) ¥
Continue chemotherapy; RT for selected patients

- Surgical resection: primary treatment modality for patients with pancreatic cancer
- Treatment is often guided by resectability, but this may vary depending on surgical judgment and experience
- The addition of postoperative chemotherapy improves overall survival, but the role of chemoradiation remains controversial.
- Complications of pancreatic cancer include :
- Malabsorption: ,pancreatic enzyme replacement
- Pain: Celiac axis and intrapleural nerve blocks

Copyrights apply


با تشکر از توجه شما
touric.com